

SUPPLEMENTAL FIGURES FOR:

Robust Surgical Approach for Cutaneous Neurofibroma in Neurofibromatosis Type 1

Bahir H. Chamseddin¹, La'Nette Hernandez¹, Dezehree Solorzano¹, Juan Vega¹, Lu Q. Le^{1,2,3}

¹Department of Dermatology, UT Southwestern Medical Center, Dallas, TX 75390

²Comprehensive Neurofibromatosis Clinic, UT Southwestern Medical Center, Dallas, TX 75390

³Simmons Comprehensive Cancer Center, UT Southwestern Medical Center, Dallas, TX 75390

Corresponding Author:

Lu Q. Le, M.D., Ph.D.

Associate Professor

Department of Dermatology

5323 Harry Hines Blvd.,

Dallas, TX. 75390-9069

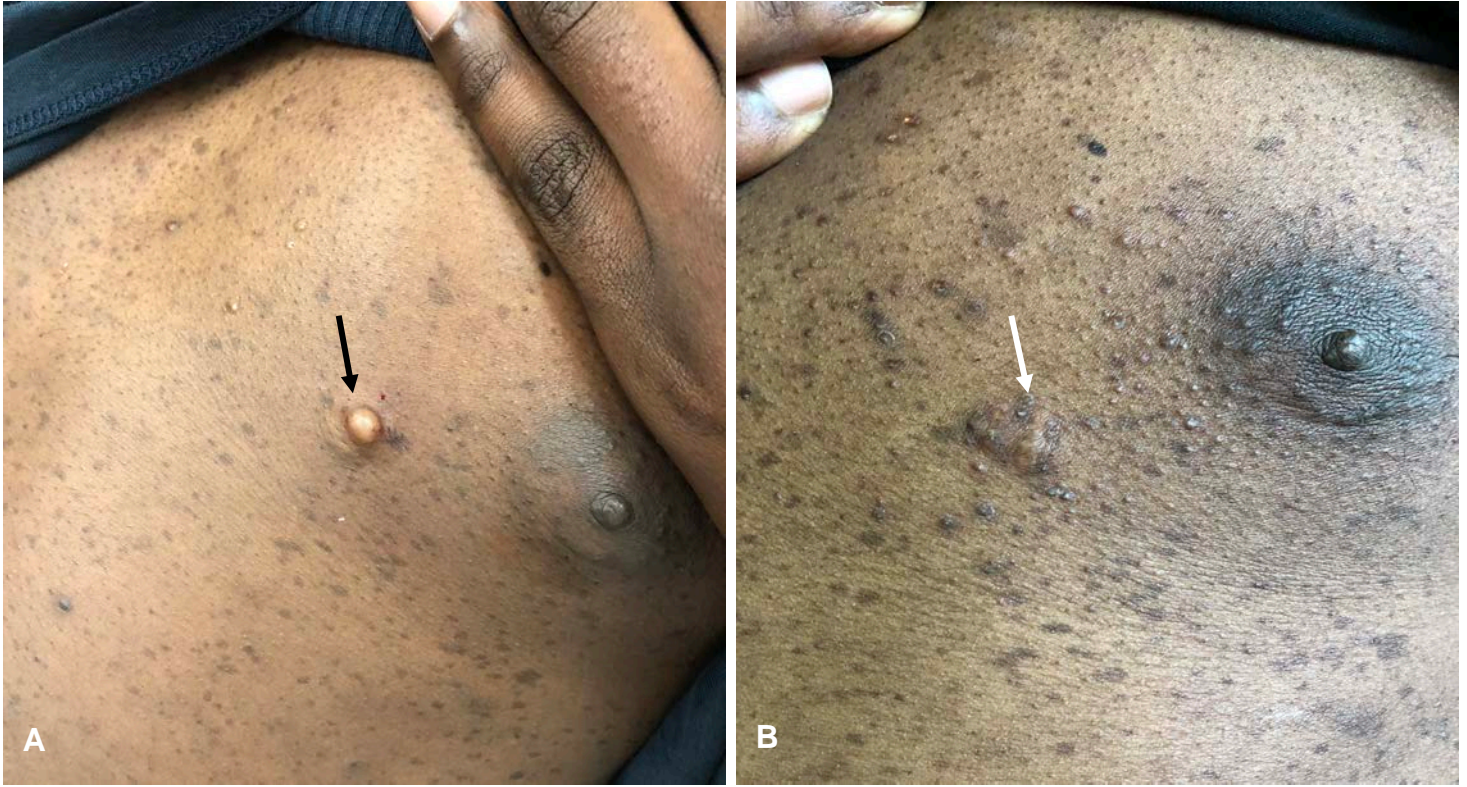Phone number: 214-648-5781

E-mail: Lu.Le@UTSouthwestern.edu

Conflicts of Interest: The authors have declared that no conflict of interest exists.

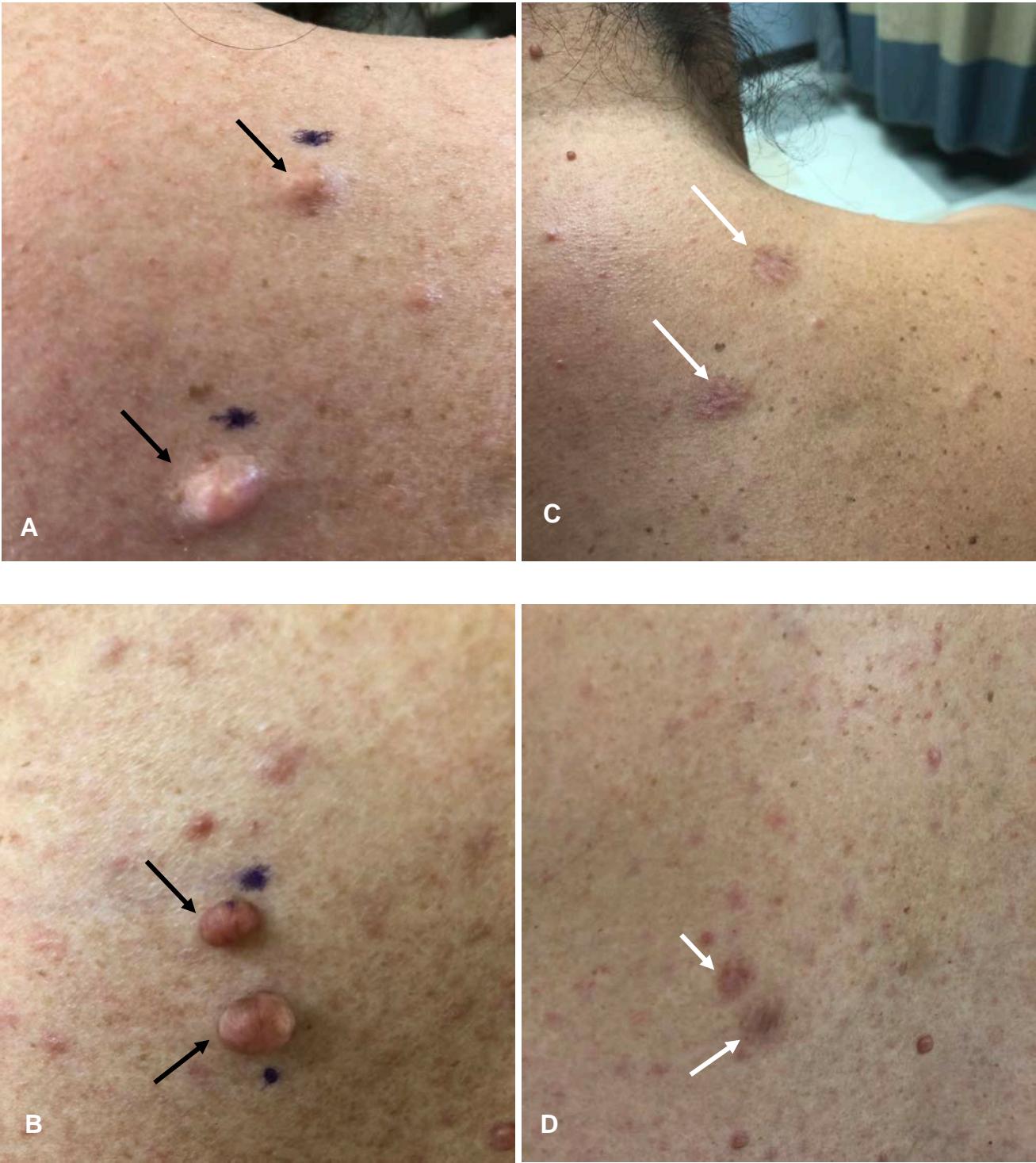Keywords: Neurofibromatosis Type 1, NF1, neurofibroma, dermal neurofibroma, cutaneous neurofibroma, treatment, elective surgery, patient satisfaction

Supplemental Figure 1



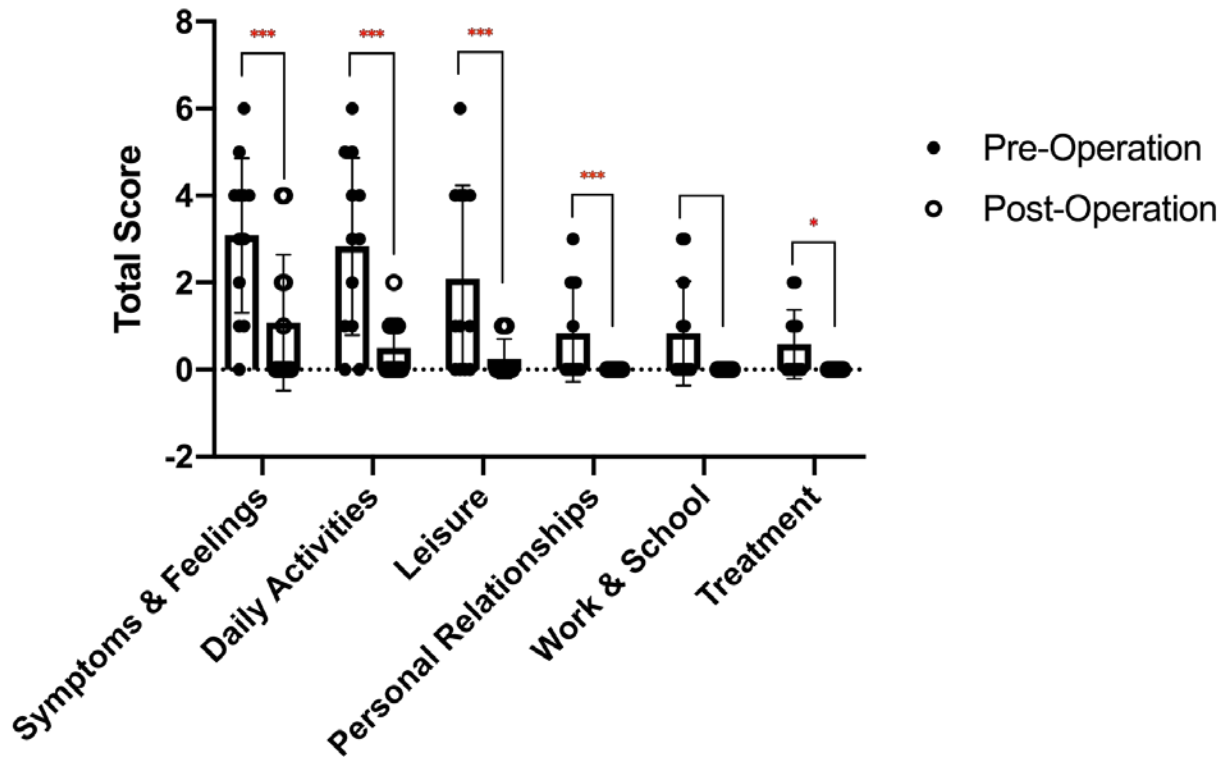
Supplemental Figure 1: 25-year-old African American male with hypertrophic scar five months after procedure. (A) Before procedure, cutaneous neurofibroma denoted with black arrow. (B) Five months post procedure, hypertrophic scar denoted with white arrow.

Supplemental Figure 2



Supplemental Figure 2: Post-Inflammatory Hyperpigmentation. (A, B) Before procedure, cutaneous neurofibromas denoted with black arrow; (C,D) Five months post procedure, post-inflammatory hyperpigmentation denoted with white arrow

Supplemental Figure 3



Supplemental Figure 3: Dermatology Life Quality Index Total Scores among patients who removed cutaneous neurofibromas.

Each dot represents one subject's response to the Dermatology Quality of Life Index

*= Significance level <0.05

**= Significance <0.01

***=Significance <0.001